



LABORATORY MANUAL FOR

# ANATOMY & PHYSIOLOGY

CONNIE ALLEN • VALERIE HARPER SIXTH EDITION

WILEY



**6<sup>th</sup>**  
EDITION

# **Laboratory Manual for Anatomy and Physiology**

*This book is dedicated to my newest granddaughter, Cassidy Joy Thomas, in addition to my other  
5 grandchildren: Michael, Jaxton, Jaden, Gianna, and Taralyn.*

—CONNIE ALLEN

*To my husband Chuck and my children Scott and Kate: Your love and support are invaluable to me.*

—VALERIE HARPER

**6<sup>th</sup>**  
EDITION

# Laboratory Manual for Anatomy and Physiology

**CONNIE ALLEN**

Edison State College

**VALERIE HARPER**

Colorado Mesa University

**WILEY**

VICE PRESIDENT AND DIRECTOR	Petra Recter
SENIOR EDITOR	Maria Guarascio
ASSOCIATE DEVELOPMENT EDITOR	Laura Rama
ASSISTANT DEVELOPMENT EDITOR	Lindsey Myers
SENIOR MARKETING MANAGER	Alan Halfen
SENIOR CONTENT MANAGER	Svetlana Barskaya
SENIOR PRODUCTION EDITOR	Trish McFadden
SENIOR PHOTO EDITOR	MaryAnn Price
SENIOR PRODUCT DESIGNER	Linda Muriello
SENIOR DESIGNER/COVER DESIGNER	Tom Nery
TEXT DESIGNER	Tom Nery
COVER PHOTO	Mark Nielsen

This book was set in 10/12 Janson Text LT Std by Aptara<sup>®</sup>, Inc. Printed and bound by Courier/Kendallville.

This book is printed on acid-free paper. ∞

Founded in 1807, John Wiley & Sons, Inc. has been a valued source of knowledge and understanding for more than 200 years, helping people around the world meet their needs and fulfill their aspirations. Our company is built on a foundation of principles that include responsibility to the communities we serve and where we live and work. In 2008, we launched a Corporate Citizenship Initiative, a global effort to address the environmental, social, economic, and ethical challenges we face in our business. Among the issues we are addressing are carbon impact, paper specifications and procurement, ethical conduct within our business and among our vendors, and community and charitable support. For more information, please visit our website: [www.wiley.com/go/citizenship](http://www.wiley.com/go/citizenship).

Copyright © 2017 John Wiley & Sons, Inc. All rights reserved. No part of this publication may be reproduced, stored in a retrieval system, or transmitted in any form or by any means, electronic, mechanical, photocopying, recording, scanning or otherwise, except as permitted under Sections 107 or 108 of the 1976 United States Copyright Act, without either the prior written permission of the Publisher, or authorization through payment of the appropriate per-copy fee to the Copyright Clearance Center, Inc., 222 Rosewood Drive, Danvers, MA 01923 (website: [www.copyright.com](http://www.copyright.com)). Requests to the Publisher for permission should be addressed to the Permissions Department, John Wiley & Sons, Inc., 111 River Street, Hoboken, NJ 07030-5774, (201) 748-6011, fax (201) 748-6008, or online at: [www.wiley.com/go/permissions](http://www.wiley.com/go/permissions).

Evaluation copies are provided to qualified academics and professionals for review purposes only, for use in their courses during the next academic year. These copies are licensed and may not be sold or transferred to a third party. Upon completion of the review period, please return the evaluation copy to Wiley. Return instructions and a free-of-charge return shipping label are available at: [www.wiley.com/go/returnlabel](http://www.wiley.com/go/returnlabel). If you have chosen to adopt this textbook for use in your course, please accept this book as your complimentary desk copy. Outside of the United States, please contact your local representative.

ePUB ISBN: 978-1-119-27916-7

The inside back cover will contain printing identification and country of origin if omitted from this page. In addition, if the ISBN on the back cover differs from the ISBN on this page, the one on the back cover is correct.

Printed in the United States of America

10 9 8 7 6 5 4 3 2 1

# Preface

**A**natomy and physiology is a challenging course, and this laboratory manual is written to help students meet that challenge. It is written for students interested in allied health fields, such as nursing; physical, respiratory, cardiovascular, or occupational therapy; radiology; and dental hygiene. This manual may be used with any two-semester anatomy and physiology textbook.

The design of this laboratory manual is based on the authors' experience as anatomy and physiology instructors and uses three learning styles: visual, auditory, and kinesthetic.

When students label diagrams, they focus on the structure rather than just the dot at the end of a line. Writing out the structure's name and pronouncing it reinforces learning. Also, having students become subjects of laboratory exercises personalizes the learning process. Animal dissections give students an opportunity to physically manipulate structures, comparing location and texture, and to observe how structures are supported, protected, and attached by connective tissue.

## Special Features Incorporated in this Laboratory Manual Include:

- This lab manual can be used for online anatomy and physiology classes. Many lab activities can be performed by students at home or used in the laboratory. Online students can also use the **Real Anatomy** Virtual Dissection program and **PowerPhys** simulated lab activities to enhance their learning.
- Just enough text is provided to introduce concepts in each section and to set up and support the laboratory section. The exercises are written so students do not need their textbooks to complete the laboratory activities.
- New material is divided into small segments, starting with simple diagrams, illustrating the basic concepts and building up to more complex diagrams. Subsequent activities add to the students' knowledge in a stepwise fashion. This is especially noticed in the skeletal and muscular exercises.
- Each exercise contains a list of objectives, materials needed for the exercise, and easily identifiable laboratory activity sections.
- Unlabeled four-color drawings, photographs, and photomicrographs are included for students to label either at home or in the laboratory. Students first write out the name of the structure to help learn it. Then the completed diagrams will be used to identify structures on models.

- Physiology experiments use students as subjects and can be completed with either simple, inexpensive equipment and materials or more complex lab setups.
- Experimental report sections after physiology experiments where students are asked to make predictions, collect and analyze data, and write simple lab reports.
- Discussion Questions are within the activities to make the students think about the material presented.
- An Answer Key is provided at the end of the laboratory manual for the activities in each exercise. Students receive immediate feedback, and they are not dependent on the instructor for the correct answers.
- “Reviewing Your Knowledge” and “Using Your Knowledge” sections follow the activities at the end of each exercise. “Reviewing Your Knowledge” provides a thorough review of the material in the exercise, whereas “Using Your Knowledge” requires students to apply information learned. Either or both of these sections may be handed in to the instructors for a grade, because neither section has answers in the back of the laboratory manual.
- Biopac Laboratory Guide Experiments are available online for several exercises.

## New Features to the Sixth Edition

- Revised Exercise 6: Tissues with many new photomicrographs.
- Revised Exercise 14: Skeletal Muscles with many new drawings and cadaver photos
- Updated drawings in many Exercises.
- Wiley Engage online platform for enhanced engagement and customization capabilities.

## Wiley Engage

Wiley Engage for Anatomy and Physiology is an innovative, dynamic online environment—designed to help you administer your lab in a personalized way. Utilizing Wiley Engage in your lab provides you with the tools and resources to create and manage effective activities and assessment strategies.

**Wiley Engage** for the Allen & Harper *Lab Manual for Anatomy & Physiology* includes:

- Complete online version of the Lab Manual, including interactive labeling exercises, for seamless integration of all content. This content can be fully customized, curated, or rearranged to better support your lab, and local content can be easily added, including your own assessment questions.

- Relevant student study tools and learning resources ensure positive learning outcomes.
- Resources like **Dissection Videos** and **Anatomy Drill and Practice** labeling help students study for laboratory practicals.
- **PowerPhys 3.1**, lab simulation software that allows students to explore physiology principles through self-contained activities. Each activity follows the scientific method containing objectives with animated review material, prelab quizzes, pre-lab reports (including predictions and variables), data collection and analysis, and a full lab report with discussion and application questions. Experiments contain real data that is randomly generated, allowing users to experiment multiple times, but still arrive at the same conclusions. These activities focus on core physiological concepts and reinforce techniques experienced in the laboratory.
- **Real Anatomy**, 3-D imaging software that allows you to dissect through multiple layers of a three-dimensional real human body to study and learn the anatomical structures of all body systems.

Please contact your Wiley representative for details about these and other resources or visit our website at [www.wiley.com](http://www.wiley.com).

## Acknowledgments

We deeply appreciate the support, instruction, and encouragement from the members of our editorial, production, and

marketing team at Wiley: Maria Guarascio, Linda Muriello, Trish McFadden, MaryAnn Price, and Alyce Pellegrino. We also wish to thank Gerard Tortora and Bryan Derrickson for producing a wonderful textbook that provided many illustrations and ideas for our laboratory manual. A special thank you to Susan Baxley for reviewing all the exercises, making suggestions and to Bob Clemence for allowing us to use his figure of the Respiratory Volumes and Capacities. A special thanks to Charles Harper for answering many clinical questions.

We also wish to thank Wynne Au Yeung at Imagineering Art for the artwork she provided for our laboratory manual. Thank you to our colleagues at Edison State College: Bob Clemence, Colleen Swanson, Jody Gootkin, Richard McCoy, Jeff Davis, Dick Felden, Lyman O'Neil, Kitty Gronlund, Tony Contino, Cheryl Black, Jed Wolfson, Jay Koepke, and Roy Hepner who encouraged us, answered our questions, and provided critiques of exercises. We also wish to thank Nicole Yarbrough George for her critique of the skeletal muscle chapter. Thank you to Chaim Jay Margolin of Regional Radiology Associates and David Michie of Clinical Physiology Associates for providing images for this manual. Special thanks to SOMSO for providing images for our online Anatomy Drill and Practice: Anatomical Models section. Thanks to contributors Jerri Lindsey, Tarrant County College, and Terry Thompson, Wor-Wic Community College.



# Contents

Preface v

## INTRODUCTION

- EXERCISE 1 **Anatomical Language** 1
- EXERCISE 2 **Organ Systems and Body Cavities** 13

## CELL AND TISSUES

- EXERCISE 3 **Compound Light Microscope** 25
- EXERCISE 4 **Cell Structure and Cell Cycle** 33
- EXERCISE 5 **Transport Across the Plasma Membrane** 43
- EXERCISE 6 **Tissues** 53

## INTEGUMENTARY SYSTEM

- EXERCISE 7 **The Integumentary System Structure and Function** 85

## SKELETAL SYSTEM AND JOINTS

- EXERCISE 8 **Bone Structure and Function** 97
- EXERCISE 9 **Axial Skeleton** 107
- EXERCISE 10 **Appendicular Skeleton** 139
- EXERCISE 11 **Joints and Synovial Joint Movements** 161

## MUSCULAR SYSTEM: SKELETAL MUSCLES

- EXERCISE 12 **Skeletal Muscle Structure** 175
- EXERCISE 13 **Contraction of Skeletal Muscle** 187
- EXERCISE 14 **Skeletal Muscles and Their Actions** 199

## SURFACE ANATOMY

- EXERCISE 15 **Surface Anatomy** 241

## NERVOUS SYSTEM

- EXERCISE 16 **Nervous Tissue** 263
- EXERCISE 17 **Spinal Cord Structure and Function** 277
- EXERCISE 18 **Spinal Nerves** 287
- EXERCISE 19 **Somatic Reflexes** 299
- EXERCISE 20 **Brain Structure and Function** 309
- EXERCISE 21 **Cranial Nerves** 333
- EXERCISE 22 **Autonomic Nervous System Structure and Function** 343
- EXERCISE 23 **General Senses** 355
- EXERCISE 24 **Special Senses** 369

## ENDOCRINE SYSTEM

- EXERCISE 25 **Endocrine Structure and Function** 401

## CARDIOVASCULAR SYSTEM

- EXERCISE 26 **Blood Components and Blood Tests** 421
- EXERCISE 27 **Heart Structure and Function** 441
- EXERCISE 28 **Cardiac Cycle** 461
- EXERCISE 29 **Blood Vessel Structure and Function** 473
- EXERCISE 30 **Blood Vessel Identification** 489

## LYMPHATIC AND IMMUNE SYSTEMS

- EXERCISE 31 **Lymphatic System Structure and Immune System Function** 517

## RESPIRATORY SYSTEM

- EXERCISE 32 **Respiratory System Structure and Function** 537
- EXERCISE 33 **Pulmonary Ventilation** 555

## DIGESTIVE SYSTEM

- EXERCISE 34 **Digestive System Structure and Function** 571
- EXERCISE 35 **Mechanical and Chemical Digestion** 599

## URINARY SYSTEM

- EXERCISE 36 **Urinary System Structure and Function** 607
- EXERCISE 37 **Urine Formation and Urinalysis** 625

## REPRODUCTIVE SYSTEMS

- EXERCISE 38 **Male Reproductive System Structure and Function** 637
- EXERCISE 39 **Female Reproductive System Structure and Function** 653

## HUMAN DEVELOPMENT AND HEREDITY

- EXERCISE 40 **Human Development** 671
- EXERCISE 41 **Heredity** 685

**Answer Key to Activities** 699

APPENDIX A: **Word Roots** 719

APPENDIX B: **Skeletal Muscle Origins and Insertions** 721

APPENDIX C: **Measurements** 727

**Index** 729



# Anatomical Language

## OBJECTIVES

- 1 Describe the anatomical position
- 2 Use anatomical and directional terms correctly
- 3 Identify the various body planes and sections

## MATERIALS

- human models or anatomical charts
- apples (1 per group) and plastic knives or scalpels
- plastic tubing (eight-inch piece per group) or plastic straw
- 5 sheep brains (for class demonstration)

**A**natomical terms describe body positions, body regions, specific body areas, and landmarks. Most of these words are derived from Latin or Greek and are often part of the names of muscles, bones, nerves, and blood vessels. Learning these terms at this time will help you throughout the course.

## A. Body Position

The **anatomical position** is the reference position anatomists and people in medical fields use to describe the location of body parts or regions. In the anatomical position, the body is erect (vertical) and facing forward; the arms are straight and at the sides of the body with the palms facing forward; the legs are straight with the feet facing forward and flat (Figure 1.1).

In the **supine position**, the body is horizontal and lying on the back. In the **prone position**, the body is horizontal and lying on the stomach.

## B. Body Regions

Body regions refer to specific areas of the body. It is important that you learn the correct boundaries for each region. The main body regions are the head, neck, trunk, upper limbs, and lower limbs. The **head** consists of the

**skull** (cranial and facial bones), and **face** (anterior portion of the head comprised of the forehead, eyes, nose, mouth, cheeks, and chin). The **neck** connects the head to the trunk.

The **trunk** consists of the **chest** (area between neck and diaphragm) that contains the heart and lungs, the **abdomen** (area between chest and hip bones) that contains digestive organs, the **pelvis** (area below abdomen that contains internal reproductive organs and urinary bladder), and the **back** (posterior portion of trunk between neck and buttocks).

The **upper limb** consists of the **shoulder** (curved area where arm attaches to upper border of trunk), **arm** (area between shoulder and elbow), **forearm** (area between elbow and wrist), and **hand** (wrist, palm, fingers).

The **lower limb** consists of the **buttocks** (rounded area on posterior surface where thigh attaches to trunk), **groin** (area on anterior surface where lower limb attaches to pelvis), **thigh** (area of lower limb between the groin and knee), **leg** (area of lower limb between knee and ankle), and **foot** (includes ankle, sole, toes).

Many anatomical terms have one or more word roots with a prefix and/or a suffix added. For example, in the word *antecubital*, *ante-* is a prefix meaning before or in front of, the word root *cubit-* means elbow, *-al* is a suffix meaning pertaining to. Table 1.1 contains anatomical terms with four different suffixes, all of which mean pertaining to. These suffixes are *-al*, *-ic*, *-ar*, and *-ary*. When suffixes like these are added to word roots they form adjectives, whereas nouns have different endings such as *-um*, *-us*, *-is*,

and *-a*. For example, *stern-* is a word root meaning chest; *sternum* is the noun and *sternal* is the adjective. Anatomical terms and their definitions are found in Table 1.1. Word roots and their definitions are found in Appendix A, as well as nouns and adjectives formed from the word roots.

### Before Going to Lab

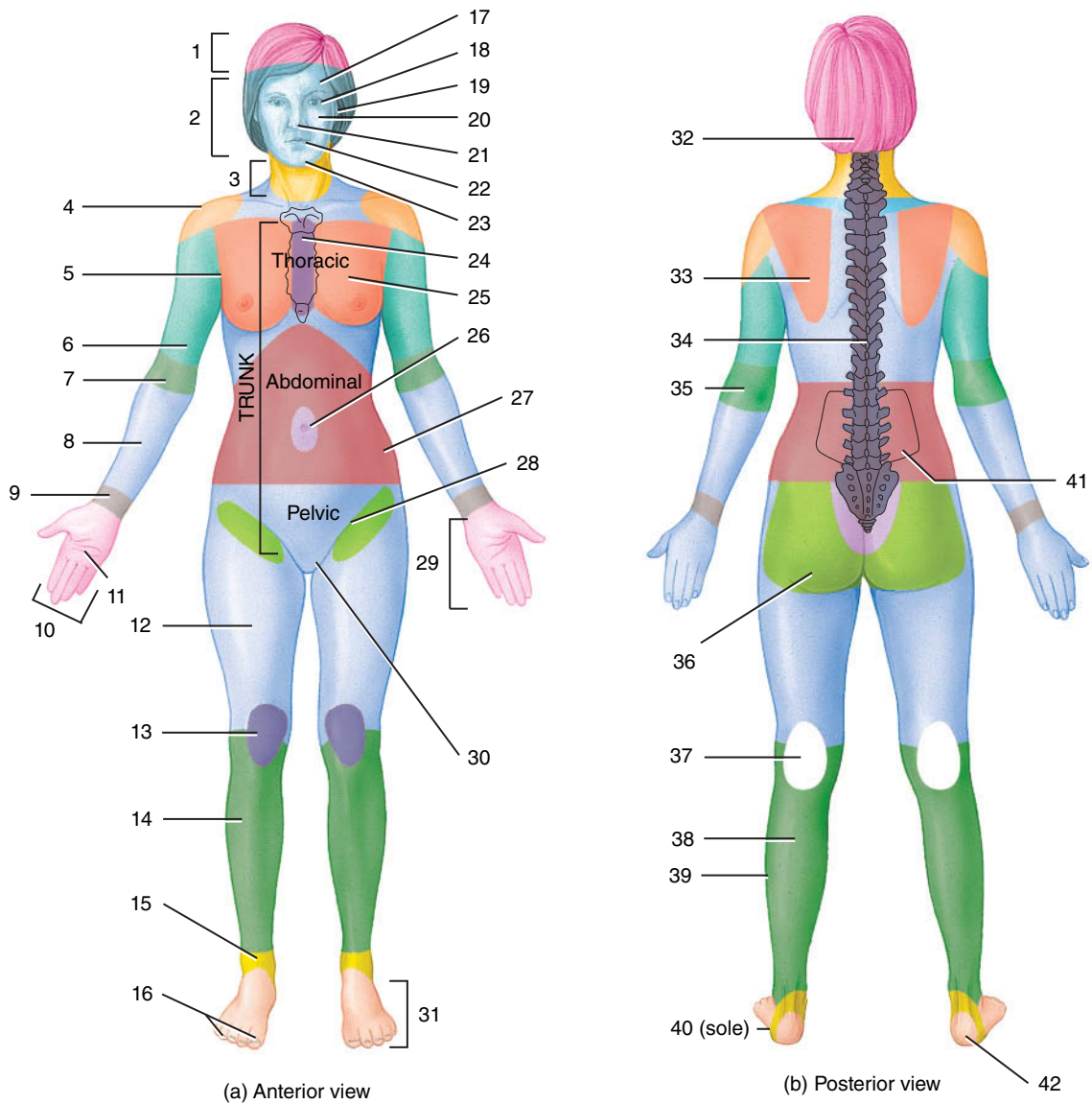
- 1 Label Figure 1.1 with the appropriate anatomical terms for each body region or area. Refer to Table 1.1.
- 2 Refer to Appendix A to review how word roots, suffixes, and prefixes are combined to form nouns and adjectives.

### LAB ACTIVITY 1 Anatomical Terms

- 1 Use anatomical and common terms to identify the specific body regions or areas on models, anatomical charts, or yourself. ■

**TABLE 1.1 Anatomical Terms**

TERM	DEFINITION	TERM	DEFINITION
<b>AXIAL</b>	Pertaining to the central part of the body, the head and trunk	<b>APPENDICULAR</b>	Pertaining to the extremities or limbs
<b>Cephalic</b> (se-FAL-ik)	Pertaining to the head	<b>Upper Limb (Appendage)</b>	
• Cranial	Pertaining to the portion of the skull surrounding the brain	• Acromial (a-KROM-ee-al)	Pertaining to the highest point of the shoulder
• Facial	Pertaining to the face	• Axillary (AX-il-ary)	Pertaining to the armpit
• Frontal	Pertaining to the forehead	• Brachial (BRAY-key-ul)	Pertaining to the arm
• Orbital	Pertaining to the eye	• Antecubital (an-teh-KYOO-bi-tul)	Pertaining to the anterior (front) surface of the elbow
• Otic (OH-tik)	Pertaining to the ear	• Olecranal (oh-LEK-ra-nul)	Pertaining to the posterior (back) surface of the elbow
• Nasal	Pertaining to the nose	• Antebrachial	Pertaining to the forearm
• Buccal (BUCK-al)	Pertaining to the cheek	• Carpal	Pertaining to the wrist
• Oral	Pertaining to the mouth	• Manual	Pertaining to the hand
• Mental	Pertaining to the chin	• Palmar	Pertaining to the palm of the hand
• Occipital (ox-SIP-i-tal)	Pertaining to the back of head	• Digital	Pertaining to the digits (fingers)
<b>Cervical</b>	Pertaining to the neck	<b>Lower Limb (Appendage)</b>	
<b>Thoracic</b>	Pertaining to the chest	• Inguinal (ING-won-ul)	Pertaining to the groin where the thigh attaches to the pelvis
• Sternal	Pertaining to the breast bone	• Gluteal (GLUE-tee-ul)	Pertaining to the buttocks
• Pectoral	Pertaining to the chest	• Femoral (FEM-or-ul)	Pertaining to the thigh
• Mammary	Pertaining to the breast	• Patellar (pa-TEL-ur)	Pertaining to the anterior (front) surface of the knee
<b>Abdominal</b>	Pertaining to the abdomen	• Popliteal (pop-lih-TEE-ul)	Pertaining to the posterior (back) surface of the knee
• Umbilical (um-BIL-ih-cal)	Pertaining to the navel	• Crural (CROO-rul)	Pertaining to the anterior (front) surface of the leg
• Coxal (COX-al)	Pertaining to the hip	• Fibular (FIB-you-lur) or peroneal (peh-RONE-ee-ul)	Pertaining to the lateral side of the leg
<b>Pelvic</b>	Pertaining to the pelvis	• Sural (SIR-ul)	Pertaining to the posterior (back) surface of the leg
• Pubic (PYOO-bik)	Pertaining to the genital area	• Tarsal (TAR-sul)	Pertaining to the ankle
<b>Dorsal</b>	Pertaining to the back	• Pedal	Pertaining to the foot
• Scapular	Pertaining to the shoulder blade region	• Plantar	Pertaining to the sole of foot
• Vertebral (ver-TEE-brul)	Pertaining to the spinal column	• Calcaneal (kal-KANE-ee-ul)	Pertaining to the heel
• Lumbar	Pertaining to the area of the back between the lowest rib and buttocks.	• Digital	Pertaining to the digits (toes)



(a) Anterior view

(b) Posterior view

(a) Anterior View

- |          |          |
|----------|----------|
| 1 _____  | 12 _____ |
| 2 _____  | 13 _____ |
| 3 _____  | 14 _____ |
| 4 _____  | 15 _____ |
| 5 _____  | 16 _____ |
| 6 _____  | 17 _____ |
| 7 _____  | 18 _____ |
| 8 _____  | 19 _____ |
| 9 _____  | 20 _____ |
| 10 _____ | 21 _____ |
| 11 _____ | 22 _____ |

(b) Posterior View

- |          |          |
|----------|----------|
| 23 _____ | 32 _____ |
| 24 _____ | 33 _____ |
| 25 _____ | 34 _____ |
| 26 _____ | 35 _____ |
| 27 _____ | 36 _____ |
| 28 _____ | 37 _____ |
| 29 _____ | 38 _____ |
| 30 _____ | 39 _____ |
| 31 _____ | 40 _____ |
|          | 41 _____ |
|          | 42 _____ |

FIGURE 1.1 Anatomical terms.

### C. Directional Terms

Directional terms are used to describe the location of body structures relative to other structures. An example of a directional term is *inferior*, which means below. It would be correct to say that the neck is inferior to the head but incorrect to say that the neck is inferior. The directional terms are listed in Table 1.2, along with an example of how they are used. Note that opposite terms are paired.

The directional terms *proximal* and *distal* apply to the point of attachment of a limb to the torso or the point of origin of a structure such as a blood vessel or nerve. These terms refer to the location of structures relative to the point of attachment or point of origin, whether they are closer (proximal) or farther away (distal).

More than one directional term can apply to describe the location of a body structure. For example, the ears are posterior and lateral to the nose.

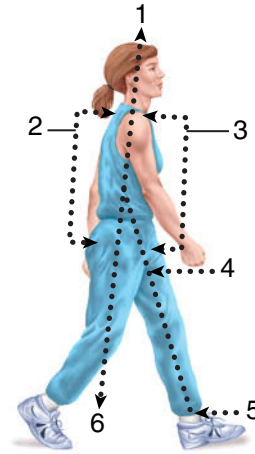
#### Before Going to Lab

- Label Figure 1.2 with the directional terms from the bulleted list by writing the term in the appropriate numbered blank.

#### LAB ACTIVITY 2 Directional Terms

- With your partner, complete the sentences using the appropriate directional term from Table 1.2. Refer to the anatomical terms in Table 1.1 and Appendix A as needed.

- The sternum is \_\_\_\_\_ to the vertebrae.
- The nose is \_\_\_\_\_ and \_\_\_\_\_ to the eyes.
- The heart is \_\_\_\_\_ to the lungs.
- The wrist is \_\_\_\_\_ to the arm.
- The right lung and right kidney are \_\_\_\_\_.
- The skin is \_\_\_\_\_ to the bones. ■



- anterior or ventral                    1 \_\_\_\_\_
- distal                                        2 \_\_\_\_\_
- inferior                                      3 \_\_\_\_\_
- posterior or dorsal                    4 \_\_\_\_\_
- proximal                                    5 \_\_\_\_\_
- superior                                     6 \_\_\_\_\_

FIGURE 1.2 Directional terms.

TABLE 1.2 Directional Terms

DIRECTIONAL TERM	DEFINITION	EXAMPLE OF USE
Superior	Above	The head is superior to the neck.
Inferior	Below	The neck is inferior to the head.
Anterior (Ventral)	Closer to front of body	The lips are anterior to the teeth.
Posterior (Dorsal)	Closer to back of body	The teeth are posterior to the lips.
Medial	Closer to midline of body	The nose is medial to the eyes.
Lateral	Farther from midline of body	The eyes are lateral to the nose.
Intermediate	Between two structures	The elbow is intermediate between the shoulder and wrist.
Ipsilateral	On same side of body	The right arm and right leg are ipsilateral.
Contralateral	On opposite sides of body	The right arm and left arm are contralateral.
Proximal	Nearer to point of attachment of limb to trunk	The elbow is proximal to the wrist.
Distal	Farther from point of attachment of limb to trunk	The wrist is distal to the elbow.
Superficial	Closer to surface of body	The skin is superficial to the muscles.
Deep	Farther from surface of body	The muscles are deep to the skin.

## D. Body Planes and Sections

Planes are flat surfaces that divide the body or organs in order to expose internal structures (Figure 1.3). The exposed surfaces produced by planes are called **sections**. **Sagittal** (*sagitta* = arrow) **planes** pass vertically through the body or organs and divide them into right and left sections (**sagittal sections**).

If a plane passes vertically through the midline and divides the body into equal right and left halves, the plane is a **midsagittal plane**, but if a plane divides the body into unequal right and left portions, it is a **parasagittal plane**.

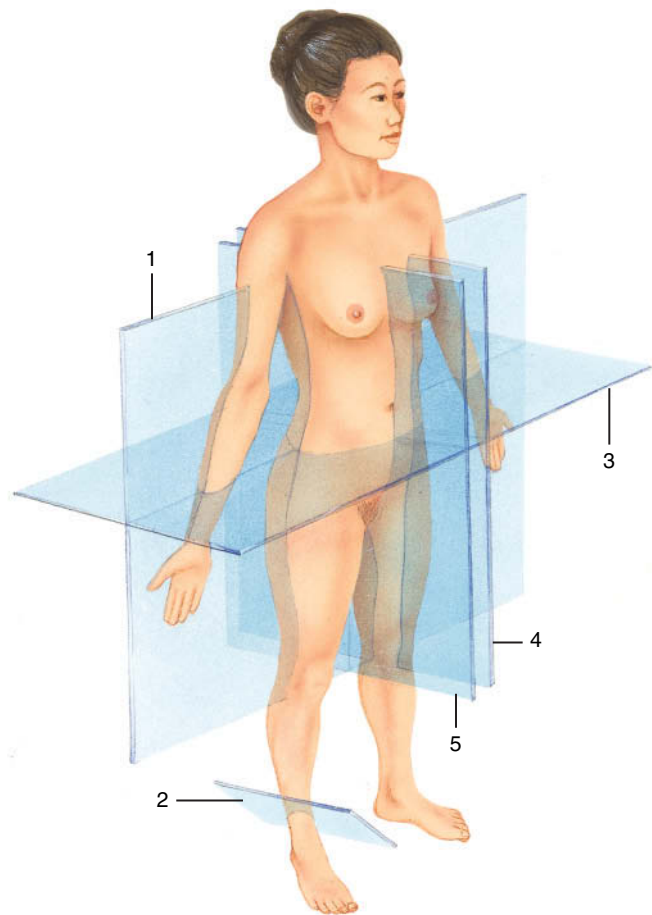
A **frontal** or **coronal plane** passes vertically through the body or organs and produces anterior and posterior sections (**frontal sections**). A **transverse plane** passes horizontally through the body and produces superior and inferior sections (**transverse sections** or **cross-sections**). **Oblique planes** pass through the body at an angle forming oblique sections.

We often look at sections of individual organs, such as blood vessels, intestines, or long bones. Sections that are produced by a plane running along the long axis of a long narrow structure are called **longitudinal sections**. Sections that are produced by a plane running perpendicular to the long axis are called **cross-sections**. Because blood vessels and intestines twist and bend, one body plane may produce longitudinal sections, cross-sections, and oblique sections of these structures.

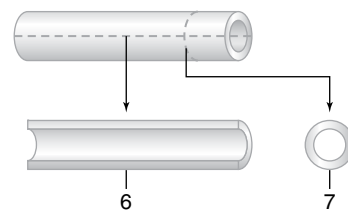
**CLINICAL NOTE:** *Transverse sections observed with computed tomography (CT) scans or magnetic resonance imaging (MRIs) are called axial sections.*

### Before Going to Lab

- 1 Label the planes in Figures 1.3(a) and the sections in Figure 1.3(b) with the terms in the accompanying bulleted list by writing the term in the appropriate numbered blank.
- 2 Identify the type of sections of the human brain in Figure 1.4.



(a) Right anterolateral view

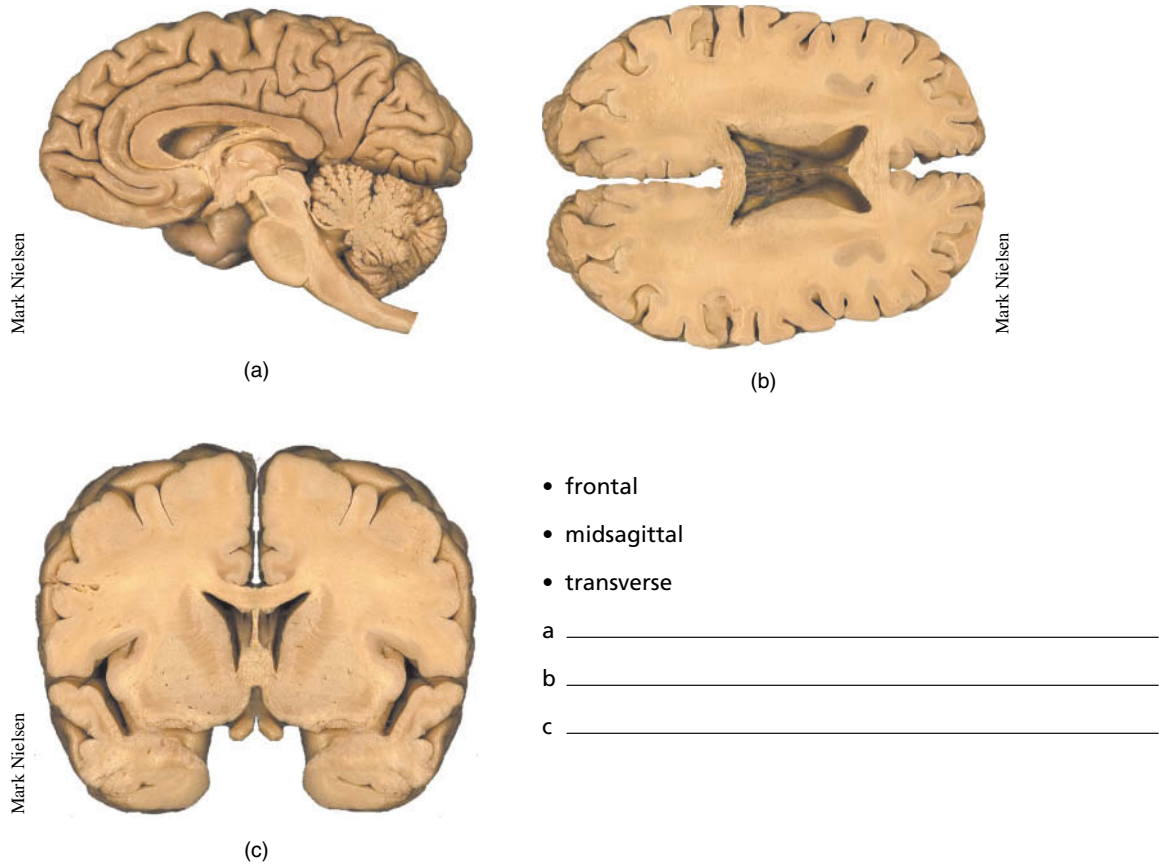


(b) Longitudinal and cross-sections

- cross-section 1 \_\_\_\_\_
- frontal plane 2 \_\_\_\_\_
- longitudinal section 3 \_\_\_\_\_
- midsagittal plane 4 \_\_\_\_\_
- oblique plane 5 \_\_\_\_\_
- parasagittal plane 6 \_\_\_\_\_
- transverse plane 7 \_\_\_\_\_

**FIGURE 1.3** Body planes and sections.





- frontal
- midsagittal
- transverse

a \_\_\_\_\_

b \_\_\_\_\_

c \_\_\_\_\_

**FIGURE 1.4** Human brain sections.

**LAB ACTIVITY 3** Body Planes and Sections

- 1 Observe sagittal, frontal, and transverse sections using an apple.
  - Working in a group, draw a face on the apple.
  - Cut sagittal, frontal, and transverse planes through the apple to make sagittal, frontal, and transverse sections.
  - Compare the appearance of the apple core in each section. Describe any difference in shape, size, and number of seed chambers.
  - Keep sections together to form a whole apple to show to your instructor.
- 2 Observe longitudinal sections and cross-sections using plastic tubing or plastic straw.
  - Observe a demonstration provided by your instructor of a tube cut along its longitudinal axis to produce a longitudinal section and a tube cut perpendicular to its longitudinal axis to produce a cross-section.
  - Obtain an eight-inch piece of plastic tubing or plastic straw and twist it so you can visualize one plane that would simultaneously divide one area of the tube

into a longitudinal section and another area into a cross-section.

- Do not cut the tube unless instructed to do so.
  - Show your instructor where a cut would produce both a longitudinal section and a cross-section.
- 3 Identify sagittal, frontal, transverse, and oblique sections on sheep brains.
    - Your instructor will display five sheep brains—one whole brain and four brains that have been cut into different sections.
    - Determine the anterior, posterior, superior, and inferior surfaces of the brains.
    - Decide which brain has been cut into sagittal, frontal, transverse, or oblique sections.
    - Compare the appearance of the different sections.

Brain 1—Whole brain

Brain 2 \_\_\_\_\_ section

Brain 3 \_\_\_\_\_ section

Brain 4 \_\_\_\_\_ section

Brain 5 \_\_\_\_\_ section





# Reviewing Your Knowledge

## EXERCISE

# 1

### A. Body Regions

Identify the body regions using common terms.

- \_\_\_\_\_ 1. The area between the groin and knee.
- \_\_\_\_\_ 2. The area between the shoulder and elbow.
- \_\_\_\_\_ 3. The area between the elbow and wrist.
- \_\_\_\_\_ 4. The area between the knee and ankle.
- \_\_\_\_\_ 5. The area of the trunk between the neck and diaphragm.
- \_\_\_\_\_ 6. The area of the trunk between the diaphragm and hip bones.
- \_\_\_\_\_ 7. The area of the trunk inferior to the hip bones.
- \_\_\_\_\_ 8. Posterior trunk that is located between the neck and buttocks.
- \_\_\_\_\_ 9. Curved area where upper limb attaches to upper border of trunk.
- \_\_\_\_\_ 10. Area on anterior surface where lower limb attaches to pelvis.
- \_\_\_\_\_ 11. Rounded area on posterior surface where lower limb attaches to pelvis.
- \_\_\_\_\_ 12. Under arm area where upper limb attaches to trunk.
- \_\_\_\_\_ 13. The leg is to the lower limb as the \_\_\_\_ is to the upper limb.
- \_\_\_\_\_ 14. The arm is to the upper limb as the \_\_\_\_ is to the lower limb.
- \_\_\_\_\_ 15. The armpit is to the upper limb as the \_\_\_\_ is to the lower limb.
- \_\_\_\_\_ 16. The ankle is to the lower limb as the \_\_\_\_ is to the upper limb.
- \_\_\_\_\_ 17. The elbow is to the upper limb as the \_\_\_\_ is to the lower limb.
- \_\_\_\_\_ 18. The shoulder is to the upper limb as the \_\_\_\_ is to the lower limb.
- \_\_\_\_\_ 19. True or False. The hand includes the wrist and fingers and the foot includes the ankles and toes.
- \_\_\_\_\_ 20. True or False. The bones of the face are also part of the skull.

## **B. Anatomical Terms**

Write the anatomical terms that the phrase or word describes. Phrases or words referring to nouns are indicated. All other phrases refer to adjectives.

- \_\_\_\_\_ 1. Navel (noun)
- \_\_\_\_\_ 2. Pertaining to the area between the neck and abdomen
- \_\_\_\_\_ 3. Pertaining to the ear
- \_\_\_\_\_ 4. Pertaining to the palm of hand
- \_\_\_\_\_ 5. Pertaining to the high point of the shoulder
- \_\_\_\_\_ 6. Pertaining to the anterior surface of the elbow region
- \_\_\_\_\_ 7. Pertaining to the face; anterior portion of the head
- \_\_\_\_\_ 8. Pertaining to the nose
- \_\_\_\_\_ 9. Pertaining to the neck
- \_\_\_\_\_ 10. Pertaining to the posterior surface of the knee
- \_\_\_\_\_ 11. Wrist (noun)
- \_\_\_\_\_ 12. Pertaining to the area between the elbow and wrist
- \_\_\_\_\_ 13. Back (noun)
- \_\_\_\_\_ 14. Armpit area (noun)
- \_\_\_\_\_ 15. Pertaining to the mouth
- \_\_\_\_\_ 16. Pertaining to the anterior surface of the knee
- \_\_\_\_\_ 17. Breast bone (noun)
- \_\_\_\_\_ 18. Pertaining to the hip
- \_\_\_\_\_ 19. Pertaining to the lateral side of the leg
- \_\_\_\_\_ 20. Pertaining to the calf
- \_\_\_\_\_ 21. Pertaining to the area between the shoulder and elbow
- \_\_\_\_\_ 22. Pertaining to the fingers or toes
- \_\_\_\_\_ 23. Pertaining to the hand
- \_\_\_\_\_ 24. Pertaining to the breast
- \_\_\_\_\_ 25. Pertaining to the cheek

- \_\_\_\_\_ 26. Pertaining to the heel
- \_\_\_\_\_ 27. Pertaining to the sole of the foot
- \_\_\_\_\_ 28. Pertaining to the groin where the thigh attaches to the pelvic region
- \_\_\_\_\_ 29. Pertaining to the head
- \_\_\_\_\_ 30. Pertaining to the chin
- \_\_\_\_\_ 31. Pertaining to the foot
- \_\_\_\_\_ 32. Pertaining to the eye
- \_\_\_\_\_ 33. Pertaining to the genital area
- \_\_\_\_\_ 34. Pertaining to the area between the hip and knee
- \_\_\_\_\_ 35. Pertaining to the area that includes the bones enclosing the brain
- \_\_\_\_\_ 36. Pertaining to the forehead
- \_\_\_\_\_ 37. Pertaining to the spinal column
- \_\_\_\_\_ 38. Pertaining to the inferior back of the head
- \_\_\_\_\_ 39. Pertaining to the anterior surface of the leg
- \_\_\_\_\_ 40. Pertaining to the area of the lower back or loin
- \_\_\_\_\_ 41. Pertaining to the trunk below the abdomen
- \_\_\_\_\_ 42. Pertaining to the area of the back that contains the shoulder blades
- \_\_\_\_\_ 43. Pertaining to the posterior surface of the elbow
- \_\_\_\_\_ 44. Arm (noun)
- \_\_\_\_\_ 45. Two terms pertaining to the chest

## **C. Body Planes and Sections**

Write the name of the plane that the phrase describes.

- \_\_\_\_\_ 1. Divides body or organ into unequal right and left sections
- \_\_\_\_\_ 2. Divides body or organ into anterior and posterior sections
- \_\_\_\_\_ 3. Divides body or organ into superior and inferior sections
- \_\_\_\_\_ 4. Divides body into right and left halves
- \_\_\_\_\_ 5. Which two planes when passed through the body would result in two sections, with each section containing a piece of the heart and a piece of each lung?